

C H A P T E R

8

USE OF FIBRIN SEALANT  
IN SHORT SCAR FACELIFT

▪ Samieh S. Rizk, M.D.

As this textbook illustrates, fibrin sealants have been used in surgical procedures for decades. First applied in intracranial surgery in 1915,<sup>1</sup> they have also been used in otolaryngologic surgery for sealing cerebrospinal fluid leaks, thoracic surgery for primary repair of thoracic duct leaks and esophageal anastomoses,<sup>2</sup> general surgery for colostomy closure and splenic repair, orthopedic surgery for tendon repairs,<sup>3</sup> and plastic surgery for skin grafts,<sup>4</sup> rhytidectomy,<sup>5</sup> blepharoplasty,<sup>6</sup> and endoscopic forehead lift.<sup>7</sup> Fibrin glue's success in limiting hematoma and seroma formation, while abolishing the need for drains in rhytidectomy, has brought this agent to the attention of aesthetic surgeons. The potential for a more rapid recovery postoperatively has further popularized it.

This chapter focuses on the role of fibrin sealant, or "tissue glue," in short scar facelift. We began using fibrin sealants over a decade ago, but until recently they were not standard in our practice. With regard to the use of the short scar incision, it has always been our practice in younger patients to perform an "upper" facelift where the incision begins on the temporal hairline, with or without a sideburn cut, and ends in the postlobule sulcus. It is only more recently, however, that we have applied the short transauricular rhytidectomy, without any hair-bearing incisions, in all patients regardless of degree of deformity, age, gender, or prior surgical history.

Although the debate continues to rage as to the optimal facelift procedure, many would agree that the ideal procedure would be one that produces the shortest scar with the least morbidity and the best result. Patients' desire for less invasive procedures with faster recoveries has served as an ongoing impetus for innovations in aesthetic surgery. Our primary motivation for incorporating the tissue sealant into the short scar facelift technique was to improve the coaptation of the dissected surfaces and to enhance flap redraping.<sup>8-10</sup> With this limited incision approach, there are three key principles. First, we continue to advocate wide skin undermining as well as redraping and repositioning of the superficial musculoaponeurotic system (SMAS)-platysma layer. Second, laxity

of the anterior neck is often addressed with a midline anterior platysma muscle resection and concomitant submentalplasty procedure with or without deep fat excision. Finally, an alteration in flap redraping with a more vertical vector than the traditional facelift approach, while adjusting the flap for dog ears, and closure of the dead space with fibrin tissue sealant are key factors. In addition to these principles, electrocautery is widely incorporated for subcutaneous tissue contouring and hemostasis. The addition of fibrin sealant (Tisseel, Baxter Corporation, Deerfield, Ill.) to facelift surgery in our practice has eliminated the use of drains in all cases. As has been reported, fibrin sealants have reduced bruising, edema, pain, hematoma, and seroma formation, enabling a more rapid recovery.

The evolution of the facelift incision into the short scar and the adjunctive use of fibrin sealant has advantages such as diminished ecchymosis and edema, with a subsequent faster recovery. Additionally, the fibrin component allows it to seal the large raw surface created during rhytidectomy and to stop oozing from smaller vessels, thus minimizing seromas, hematomas, bruising, and edema. Perhaps the most alluring advantage for patients who undergo the short scar facelift is the freedom it allows women to style and wear their hair up without altering their hairline position and men to obtain short haircuts without concern that a hairline scar or distortion might be exposed.

## FIBRIN SEALANT BASIC PHYSIOLOGY

Fibrin sealant is a physiologic, nontoxic hemostatic agent that is partially derived from human plasma. The sealant components of human fibrinogen, human thrombin, and bovine aprotinin stimulate the natural process of healing by simulating clot formation at the final phase of coagulation.<sup>3</sup> Given its derivation, however, the fear of viral transmission initially limited its use. Although viral transmission remains theoretically possible, several measures have been taken to virtually eliminate this possibility. Careful selection of plasma donors who are tested for viral serology serially over time, followed by a two-step vapor heating process of screened samples, helps maintain an excellent safety profile.<sup>11</sup> Fibrin sealant has been used in more than eight million surgical procedures since it was first marketed in 1983, and to date there have been no confirmed cases of HIV or hepatitis A, B, or C acquired from its use.<sup>11,12</sup> Introduction of the spray applicator to facilitate mixing of the product and the atomizer to evenly distribute the sealant has also contributed to the acceptance of this product.

## Indications for Use

Fibrin sealant firmly adheres to connective tissue and has elastic properties that enable it to contour over pulsating areas. It is ideal for use over small areas of oozing but is not indicated for arterial bleeding. Fibrin sealant is indicated for

controlling oozing on large raw surfaces.<sup>12</sup> It has not been associated with any caustic tissue damage when it is applied locally and is completely absorbed within 1 to 2 weeks.<sup>13</sup> Early forms of fibrin sealant had higher sodium content that rendered the clots formed transparent, and more brittle. The low sodium content of newer formulations enables the thrombin to convert the fibrinogen to fibrin on the tissue surface. This creates a fibrin matrix with structured strands that are more effectively cross-linked by factor XIIIa, forming a stronger visible clot.<sup>13</sup> Once the clot is formed, the bovine aprotinin component, an antifibrinolytic agent, reduces the rate of clot lysis by endogenous plasmin.<sup>14</sup> By sealing the raw surfaces of capillaries, postoperative bleeding, edema, pain, and the potential for hematoma formation are minimized.

### TIMING AND APPLICATION OF SEALANT

The spray application device allows maximal mixing and application of a thin layer of sealant. A thinner, less dense layer of fibrin is recommended to provide a more physiologic approximation of tissue and thus facilitate wound healing.<sup>7</sup> A single 2 ml package applied with the dual-injection system can cover a surface area of approximately 200 cm<sup>2</sup>. The cost is partially offset by the savings from omitted drainage tubes and decreased recovery time.<sup>15</sup> Once it is evenly sprayed, the skin flap is held in position for 3 minutes until set into position. The 45-minute preparation time can easily be performed during surgery by ancillary nursing staff, but the sealant must be maintained at 37° C after preparation. If the product cools, it becomes more viscous, and effective application is compromised.<sup>3</sup>

It is possible to extract the patient's own fibrinogen preoperatively to prepare autologous fibrin sealant. Indeed, our first experience with tissue sealants over a decade ago was with these products. One commercially available kit enables the physician to extract 4 ml of fibrin sealant from 120 ml of the patient's plasma<sup>16</sup>; however, this process is time consuming and requires more perioperative planning. Other available hemostatic agents include the following: autologous platelet-rich plasma combined with bovine thrombin and calcium chloride (platelet gel), autologous platelet-poor plasma rich in fibrinogen mixed with thrombin and calcium chloride in a 10:1 concentration (fibrin glue), and exogenous human or bovine thrombin spray.<sup>16,17</sup> Autologous platelet gel and fibrin glue require preparation in an autotransfusion machine utilizing automated centrifugation and are less effective hemostatic agents than commercially available preparations.<sup>16</sup>

### PREPARATION OF MATERIAL

Tisseel VH fibrin sealant comes prepackaged with four vials in each kit: a sealer protein concentrate (human), a fibrinolysis inhibitor solution (bovine), thrombin (human), and a calcium chloride solution (Fig. 8-1, A). Thrombin is

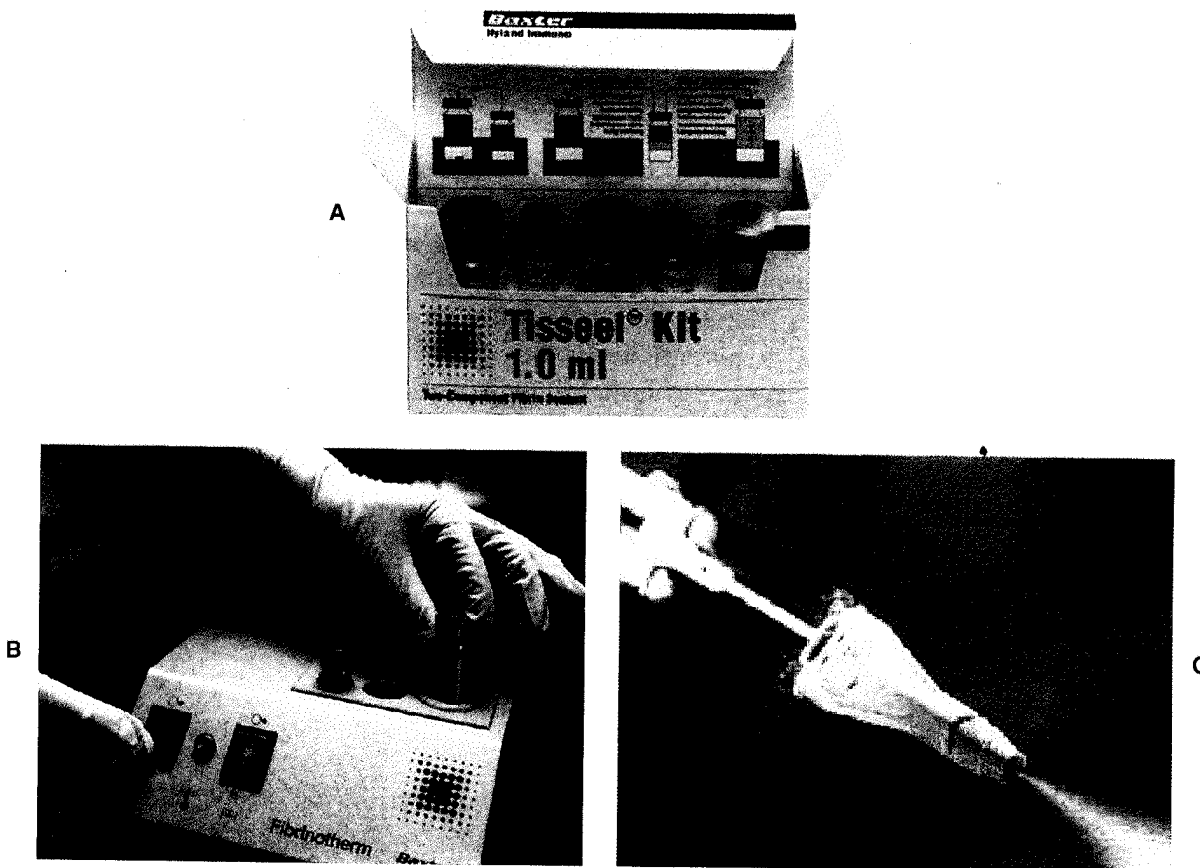
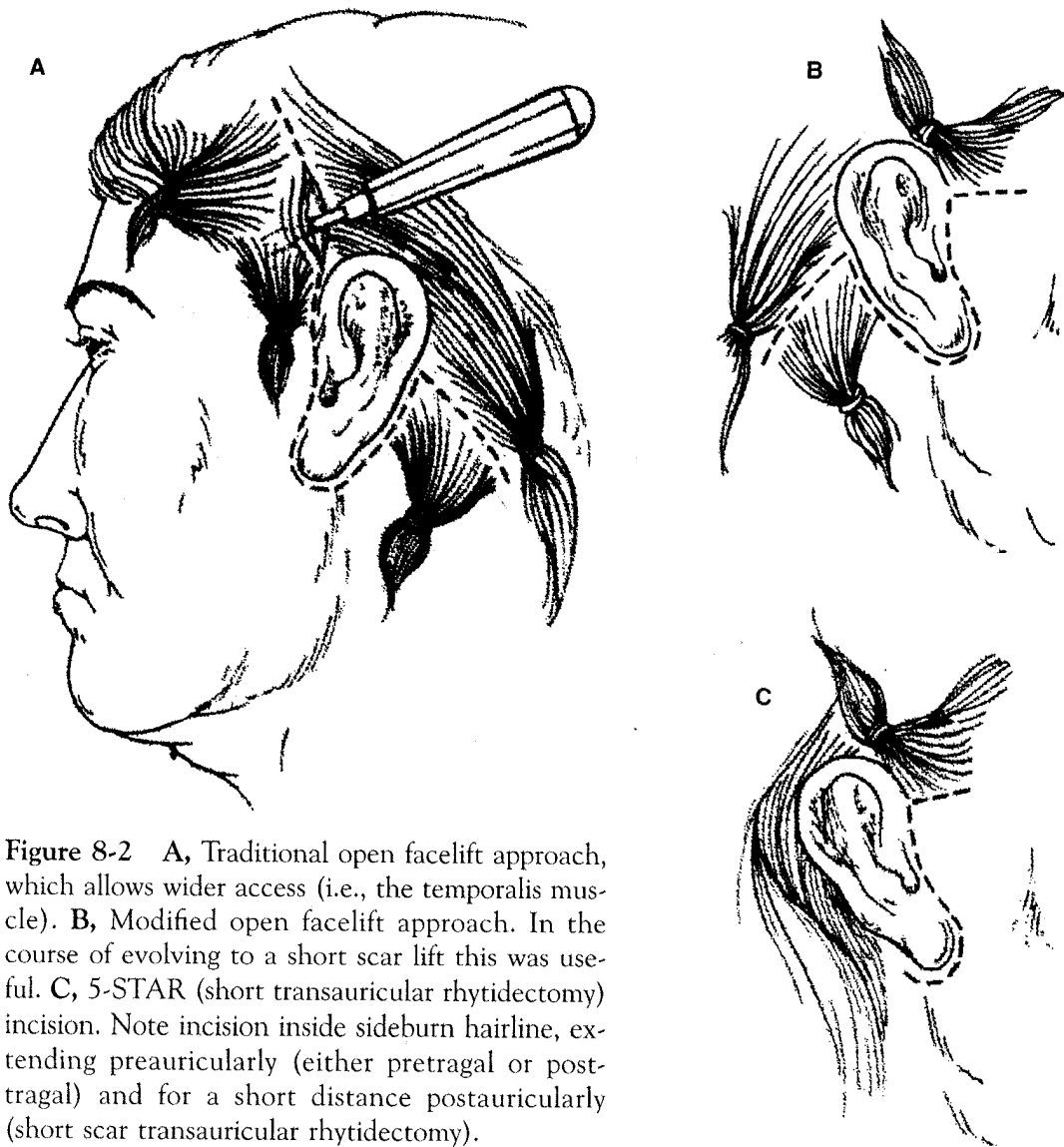


Figure 8-1 A, Fibrin sealant kit. B, Heating device for sealant. C, Dual-projection delivery aerosolizing syringes.

an enzyme that converts fibrinogen into fibrin, which is stabilized by the fibrinolysis-inhibitor enzyme. Preparation of the glue involves heating the sealer protein and fibrinolysis inhibitor for 10 minutes and then mixing them together to make the sealer protein solution. The thrombin and calcium chloride solution are then combined to form the thrombin solution. The sealer protein solution and the thrombin solution are then placed in separate syringes in the dual-injection device. The dual-injection device is then connected to the pressurized nitrogen gas tank, which aerosolizes the glue into a fine mist (Fig. 8-1, C). These two components are then sprayed together in equal amounts and mixed in the recipient tissue evenly on the flap and raw surfaces, where they polymerize to form the fibrin clot. The aerosolizing process prevents clumping for an even distribution of the glue into the recipient flap. A 2 ml kit is used for each facelift (0.75 ml per side and 0.50 for the submental wound). A 5 ml kit is also available.

## SURGICAL TECHNIQUE

The short scar facelift technique is a result of a continuous evolution from the traditional "open" facelift incision (Fig. 8-2, A), into the "modified" open technique (Fig. 8-2, B), and finally into the short scar facelift or the 5-STAR (short transauricular rhytidectomy) approach (Fig. 8-2, C). All of the patients who have had this short scar facelift also had concomitant suction-assisted lipoplasty (SAL) as indicated, and most (66%) underwent a submentalplasty. The short scar approach provides a shorter, more appealing, and well-hidden scar, essentially no hair abnormalities, potentially shorter operative time, and greater patient acceptance at the expense of a slightly narrower operative field with limited access to the orbicularis oculi muscle and temporalis muscle.



**Figure 8-2** A, Traditional open facelift approach, which allows wider access (i.e., the temporalis muscle). B, Modified open facelift approach. In the course of evolving to a short scar lift this was useful. C, 5-STAR (short transauricular rhytidectomy) incision. Note incision inside sideburn hairline, extending preauricularly (either pretragal or posttragal) and for a short distance postauricularly (short scar transauricular rhytidectomy).

## Incision Placement

The short scar incision begins in the horizontal aspect of the sideburn, extends to the preauricular region (either pretragal or post-tragal), curves around the ear lobe posteriorly up to the postauricular notch, ending 2 to 3 cm from the lobule. It spares incisions in the temporal, most of the postauricular sulcus, and the mastoid areas (see Fig. 8-2, C).

## Preoperative Preparation

Sequential pneumatic compression devices are applied in all patients. Intravenous sedation is administered by the anesthesiologist, and local anesthesia (100 ml of normal saline, 100 ml of 1% lidocaine, and 1 ml of epinephrine) is injected by the surgeon. The patient is then prepared and draped, and povidone iodine (Betadine)-soaked cotton plugs are placed in the ear canals. Broad-spectrum systemic antibiotics are given.

## Technique

The operation begins with liposuction of the neck with a 2.4 mm Mercedes cannula. Liposuction of any other facial sites is done with a 1.8 mm Mercedes cannula as indicated. Any necessary fat grafting or repositioning follows. The short scar facelift requires additional midline platysma work, accounting for the higher rate of submentalplasty than is done with the traditional facelift (66% vs. 10.6%) in our series. Through a submental incision the midline platysma is isolated, and a wide-strip wedge platysma excision is performed to shorten redundant platysma muscle. When submuscular fat excision is indicated, the exposed fat deep to the platysma muscle is excised under direct vision. The medial borders of the platysma muscle are then identified, and back-cut incisions are done in the muscle at the level of the hyoid bone. The medial borders of the platysma are then sutured in the midline with a nonabsorbable suture. This suturing begins inferiorly and runs continuously to the chin and is reinforced with a second layer of interrupted sutures. This medial vector pull on the platysma is important for defining the cervicomental angle and for the redraping of excess skin into the submental hollow that occurs with the short scar facelift. It is not necessary or desirable to have excess lateral vector pull on the platysma. During the evolution of the technique an ellipse of excess submental skin occasionally was removed at the submentalplasty incision. Later we used subcutaneous quilting sutures to tack the flap down, and we also used a drain through the submental incision. With the introduction of the tissue glue, these maneuvers became superfluous. The midline neck is opened at the beginning of surgery, and it is closed after all other incisions have been closed to allow observation for final hemostasis.

We have found that "fatty necks," after being aggressively defatted, often have a surprising degree of tissue elasticity and retraction, allowing less skin excision

than would be expected. In contrast, thin necks in older patients with "chicken skin" lack elasticity, and have poor collagen structure in addition to the diminished number of pilosebaceous units. Consequently, no amount of excessive pulling or tightening will ultimately overcome these characteristics. Indeed, attempting to compensate in these situations by excessive pulling via any surgical approach is a futile exercise that does not benefit poor quality skin.

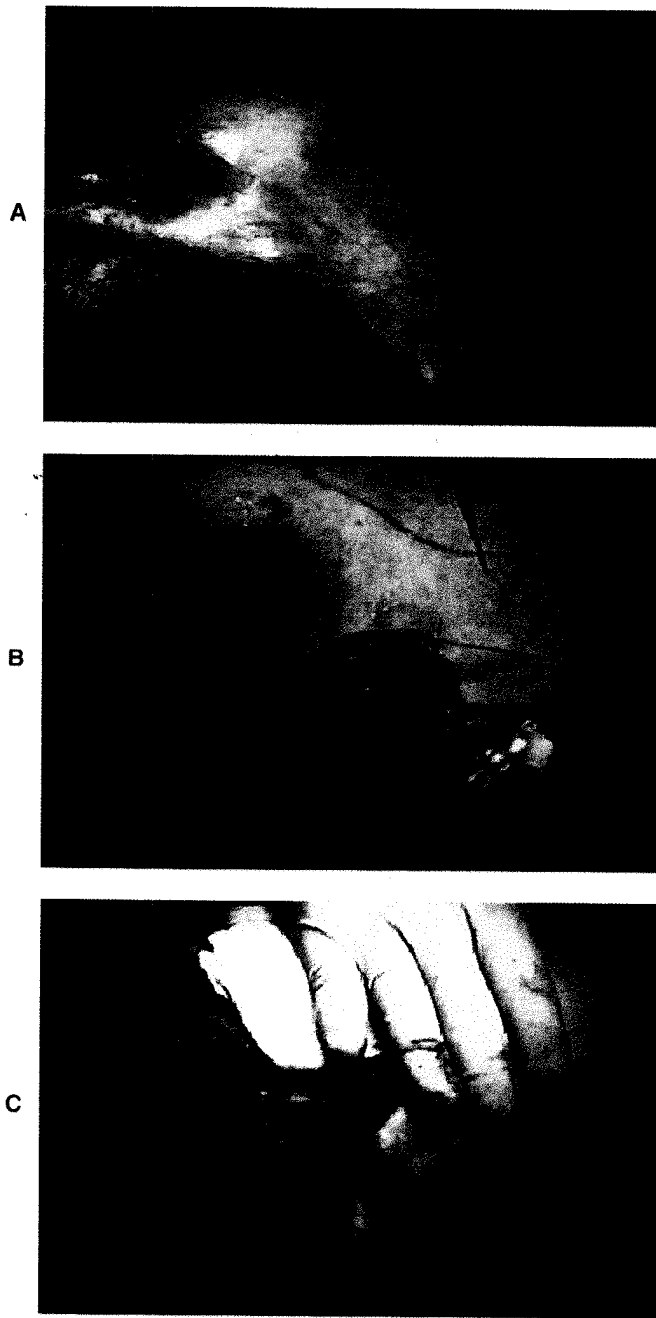The face and neck skin is undermined widely beyond the sternocleidomastoid muscle and then across the cheek and along the jawl, freeing any retaining ligaments. The SMAS in the face is identified and addressed with either an SMAS resection, SMAS plication, or anterior imbrication. Final hemostasis and aggressive subcutaneous tissue contouring are performed with a ball tip electrocautery. Next, the skin flaps on one side are grasped at the level of the helix with an allis clamp and posteriorly with a skin hook. The flaps are then re-draped obliquely (allis) and vertically (skin hook), so that the mandible no longer represents a "border" to the advancement of the neck skin (Fig. 8-3, A). This is done while adjusting the flap position to minimize bunching at the proximal (anterior end of the sideburn) and distal (posterior lobule) incisions.

After the SMAS is tightened and the skin flaps are rotated, positioned, trimmed, and tacked, the tissue glue is sprayed in an even, thin layer (0.75 ml per side) on the undersurface of the flap and on the raw dissected surfaces through the sideburn, preauricular, and postlobule incisions (Fig. 8-3, B). The fibrin sealant is sprayed in 60 seconds or less, and then external gentle pressure must be applied to the flaps with moist gauze for 3 minutes (Fig. 8-3, C) for a total time of 4 minutes. During this period the preauricular and transverse sideburn incisions are closed with 4.0 and 5.0 nylon running sutures, and the postlobule skin requires "walking out" toward the distal part of the incision as it is closed with staples. The addition of the tissue glue provides a significant draping advantage in the neck and postauricular region. At the completion of one side, the patient is turned and the other side is operated on. After repeating the process, we return our attention to the submental wound. The submental incision is again inspected, final hemostasis is obtained, and the remaining sealant is sprayed as described above. Approximately 1.5 ml of the sealant is used for both sides of the face (0.75 ml per side), and the remainder 0.5 ml is used in the submental pocket. A dressing consisting of three rows of open 4 × 8 gauze pads is applied and secured with a surgical net dressing.

Postoperative instructions include the following:

1. Vigorous pulmonary care, early ambulation, and supplemental oxygen
2. Analgesics, antiemetics, antihypertensives as indicated, and homeopathic medications
3. Limited activity; no bending or straining
4. Cold compresses
5. Routine hair care and grooming but no scrubbing of the face

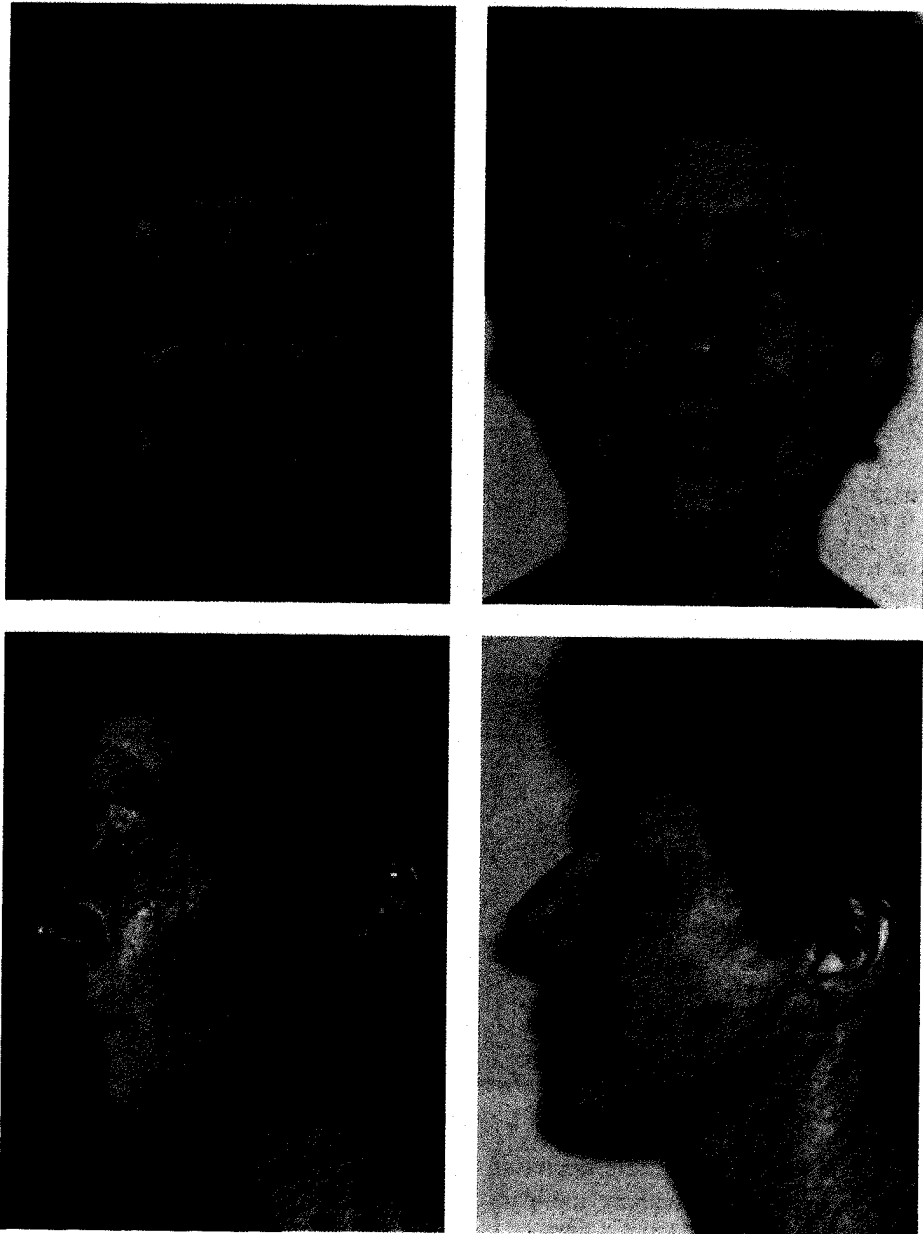




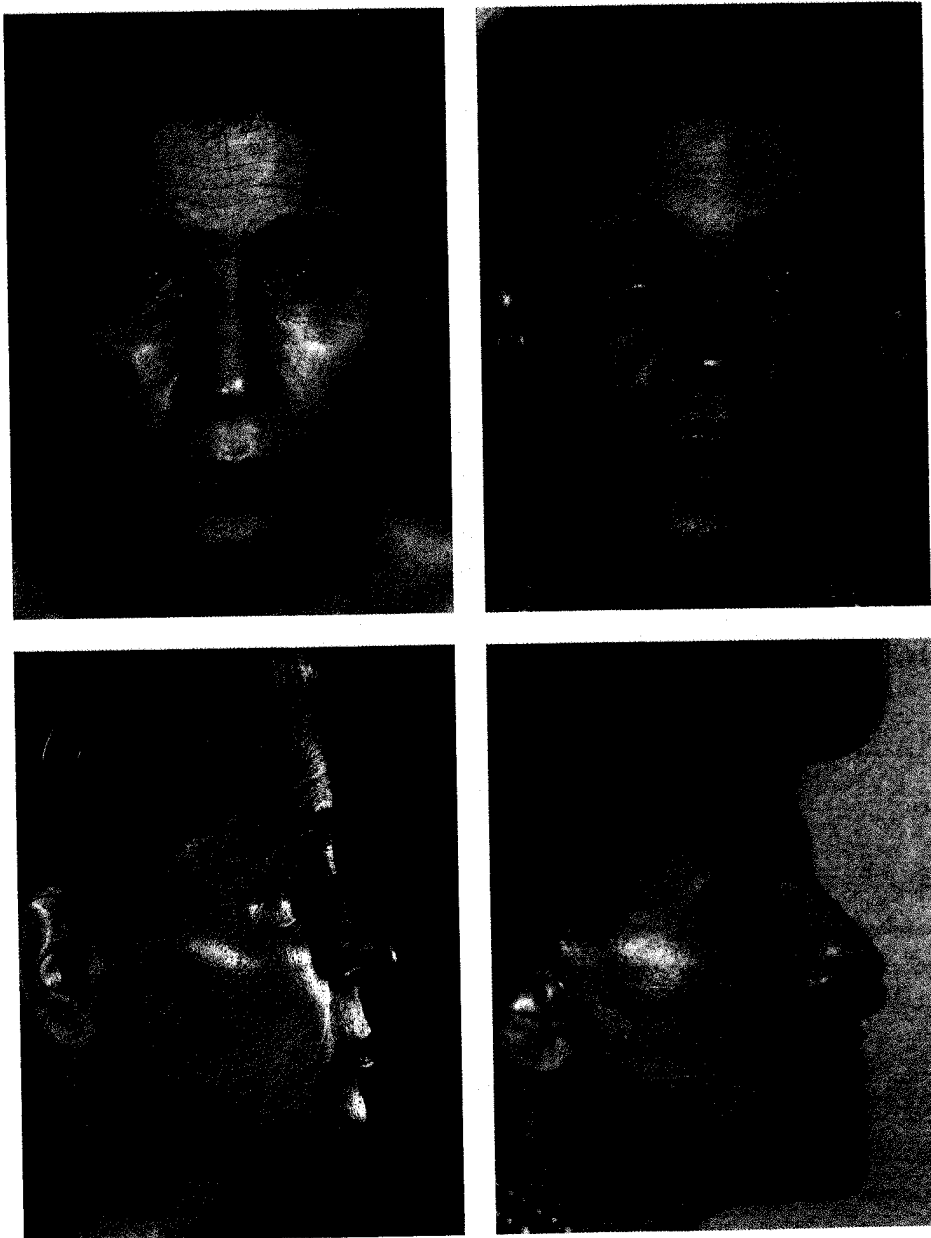
**Figure 8-3** A, Flap redraping in an oblique and vertical vector prior to sealant application. Note the blue circle depicting the area of the jowl that was liposuctioned. B, Intraoperative fibrin sealant application with dual-injection device prior to closing. Key sutures at the helical rim and tragus. The preauricular suture begins at the lobule and is then used in a running fashion up to the helical rim. Note the redundant postauricular skin that redrapes and flattens. This is aided by the fibrin sealant and “walking out” the excess tissue while closing with staples. C, Fibrin sealant is applied within 1 minute and manual pressure for 3 minutes after application. During this time, wounds are closed.

### CASE EXAMPLES

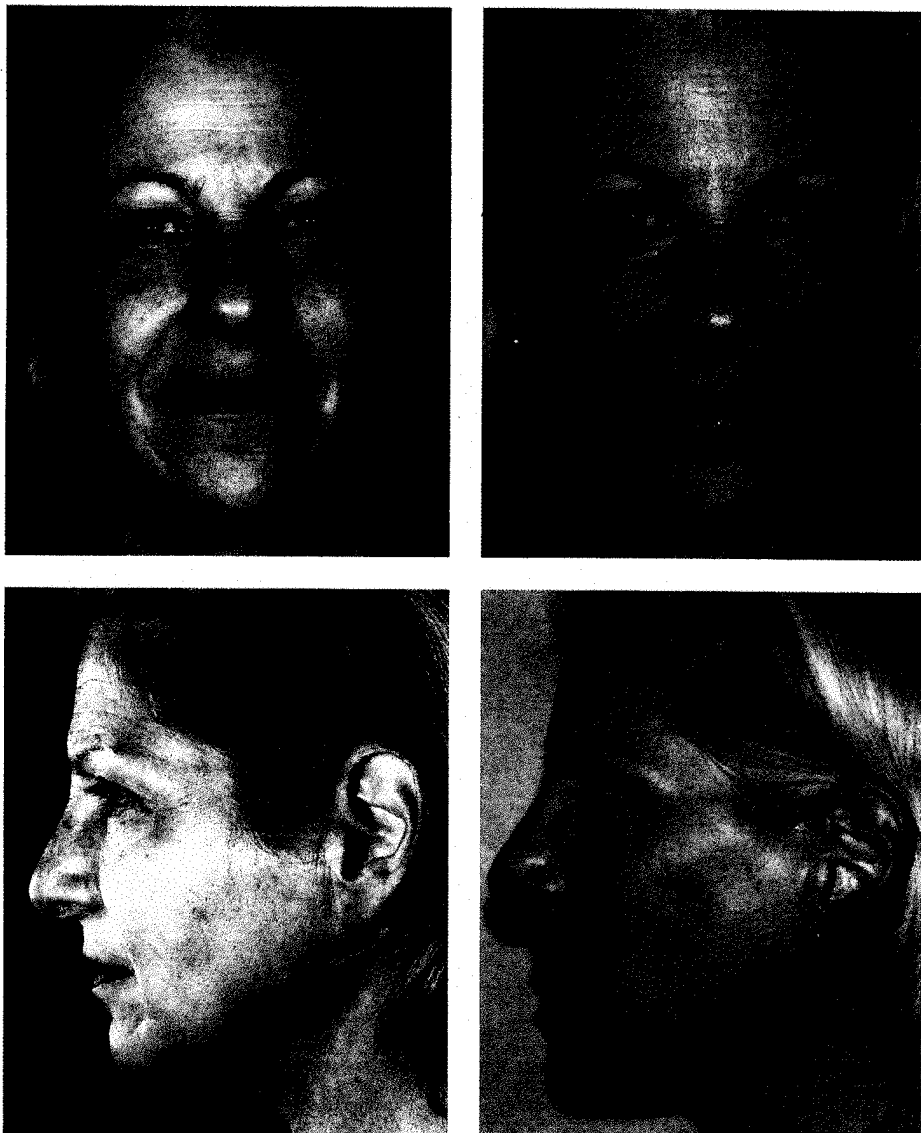
The following are cases randomly selected from our series of 427 patients, illustrating the use of fibrin sealant in short scar facelift.



This is a 60-year-old woman who underwent short scar facelift, submentalplasty, upper and lower blepharoplasty, and periocular and perioral erbium laser skin resurfacing. Early postoperative views: Note the improvement in neck contour with the short scar facelift.



This is a 58-year-old woman who underwent a short scar facelift, submentalplasty, anterior browlift, and perioral erbium laser skin resurfacing. Postoperative views shown at 3 months.



This is a 64-year-old woman who underwent a short scar facelift, submentalplasty, and upper and transconjunctival lower eyelid. Early postoperative views.

### POTENTIAL PROBLEMS AND COMPLICATIONS

Application of the glue without the aerosolized sprayer may cause clumping and deposition of too much glue. Evenly spraying the glue on the flap and raw surfaces prevents pooling of the product, which can lead to improper coaptation of the flaps. Timing of glue application is important to prevent improper redraping. Application of glue early without complete flap redraping may cause incorrect redraping and improper vectors on the flaps. Finally, the glue is not a substitute for meticulous hemostasis and will not stop arterial bleeding or vigorous venous bleeding.

The short scar facelift may cause temporary bunching in the temporal and postauricular regions that should be adjusted intraoperatively, although small residual bunching quickly resolves. The short scar incision does not provide access to the temporal region. Also, in patients with severely damaged neck skin, it does not allow excessive "pulling" or "tightening," which, however, we do not believe would compensate for the damaged collagen and elastin that is the etiology of the problem. Rather, a process that theoretically improves the damaged skin, such as topical chemicals or nonablative lasers, radiofrequency systems, or intense pulse light therapy, would be more appropriate.

Hematomas are the most common complication of facelift surgery and occur in from 4% to 15% of patients.<sup>18</sup> In our series of 427 consecutive patients, none of the final 188 patients who were treated with tissue glue experienced hematoma or seroma formation requiring reoperation. There were cases of smaller fluid collections requiring needle aspiration in the office. Hematoma formation can lead to tissue ischemia, prolonged facial edema, hyperpigmentation, reoperation, and patient dissatisfaction. Traditionally the use of vacuum drains has been recommended to diminish fluid collections and "reduce" the incidence of hematoma formation postoperatively.<sup>19</sup> Drains, however, are associated with morbidity, which may include infection, tracts at the site of drain removal, painful extraction, the possibility of injury to a vessel upon drain removal, and the increased nursing care required for drains. At present the use of drains is often advised; however, based on our experience, the adjunctive use of fibrin sealant in short scar facelift surgery appears to eliminate the need for routine drainage in facelift surgery.

Other studies corroborate these findings. One randomized, double-blind trial of 20 patients compared the drain output after unilateral application of fibrin sealant and the contralateral application of placebo during bilateral facelift. Although no patient incurred the complication of hematoma or seroma, the average drainage on the treated side was 10 ml, significantly less than the control side, which drained an average of 30 ml.<sup>14</sup> Other retrospective studies of patients who underwent rhytidectomy, half with and half without the adjunctive use of fibrin glue, revealed significantly less postoperative ecchymosis and hematoma formation despite the omission of drains and compressive dressings and more rapid recovery in the fibrin glue treatment arms.<sup>8,20</sup>

In this series of 427 consecutive short scar facelift patients, complications included the following:

- Two cases of preauricular skin ischemia (among the first 40 patients who did not have fibrin sealant)
- Two temporary cervical nerve branch injuries (resolved within 6 months)
- Five scar revisions (3 sideburns, 2 post-lobule)
- One deep venous thrombosis/pulmonary embolism (in a patient undergoing multiple face and body procedures)
- Five patients with firm, indurated anterior platysmorrhaphy fullness necessitating treatment

### KEY POINTS TO CONSIDER IN USING FIBRIN SEALANT

- Education of operating room staff and surgical assistant to the sequence of events using the sealant
- Advance planning for preparation of the product
- Proper mixing of the solution
- Appropriate time of introduction of the solution
- Recommended dividing of the 2 ml among the two halves of the face (0.75 ml per side) and the submental region (0.5 ml)
- Thin, evenly applied layer utilizing the spray application device
- Aerosolization over 1 minute followed by application of continuous pressure for 3 minutes
- Standard hemostasis
- Elimination of the need for vacuum drains

### CONCLUSION: OUR APPROACH TO THE USE OF TISSUE GLUES IN THE SHORT SCAR TRANSAURICULAR RHYTIDECTOMY (5-STAR)

The short scar facelift allows all facelift patients to avoid any hair-bearing incisions; consequently alopecia and hairline abnormalities are eliminated, as are thickened mastoid scars and certain other flap problems. This has resulted in a high degree of patient acceptance. The shift away from a traditional, larger incision to a short incision for all patients is an example of how reconsidering time-honored dogma can change longstanding medical practice (i.e., a short incision was only useful in younger patients). The use of Tisseel fibrin glue has enhanced the efficacy of the procedure by reducing fluid collections, shortening the recovery process, eliminating the use of drains, and facilitating flap repositioning. This series demonstrates our results with the short scar facelift in a large series of 427 consecutive patients by the senior author (A.M.). This series includes men and women ranging in age from 34 to 80, and encompasses those undergoing primary, secondary, or more facelifts. Submentalplasty was performed on 282 patients (66%) who underwent the short scar facelift versus 10.6% of facelift procedures performed with the traditional technique. Concomitant aesthetic procedures were performed on 295 (69%) patients. Fibrin sealant aerosolized via a spray application device was done to achieve cost-effective, superior distribution of a critically thin sealant layer in the last 188 consecutive patients. In patients receiving the fibrin sealant, vacuum drains were not placed postoperatively. Although hematomas remain the most common complication after facelift surgery, none of the 188 patients treated with tissue glue in this series of 427 patients experienced hematoma or seroma formation that required a return to the operating room. At present, the use of drains in facelift surgery remains an unresolved question; however, based on this and other series<sup>8,14,20</sup> the adjunctive use of fibrin sealant significantly minimizes postoperative bruising, edema, pain, and the risk of hematoma or seroma and apparently also eliminates the need for routine drains in rhytidectomy.

## REFERENCES

1. Grey EG. Fibrin as a hemostatic in cranial surgery. *Surg Gynecol Obstet* 21:452, 1915.
2. Dresdale A, Bowman FO Jr, Malm JR, Reemtsma K, Smith CR, Spotnitz HM, Rose EA. Hemostatic effectiveness of fibrin glue derived from single-donor fresh frozen plasma. *Ann Thorac Surg* 40:385-387, 1985.
3. Baxter Corporation. Tisseel Vapor Heated Fibrin Sealant. Data on file, Pamphlet 006031, 2002.
4. Bronstedt S, Olson S, Rank F. Wound healing and formation of granulation tissue in normal and defibrinogenated rabbits. *Eur Surg Res* 10(Suppl 10):104, 1978.
5. Marchac D, Sandor G. Face lifts and sprayed fibrin glue: An outcome analysis of 200 patients. *Br J Plast Surg* 47:306-309, 1994.
6. Mandel MA. Closure of blepharoplasty incisions with autologous fibrin glue. *Arch Ophthalmol* 108:842-844, 1990.
7. Marchac D, Ascherman J, Arnaud A. Fibrin glue fixation in forehead endoscopy: Evaluation of our experience with 206 cases. *Plast Reconstr Surg* 100:704-712, 1997.
8. Matarasso A. Facialplasty. *Dermatol Clin* 15:649-658, 1997.
9. Matarasso A, Elkwood A, Rankin M, Elkowitz M. National plastic surgery survey: Face lift techniques and complications. *Plast Reconstr Surg* 106:1185-1195, 2000. (Cited in Year Book of Plastic and Aesthetic Surgery. St. Louis: Mosby-Year Book, 2002).
10. Nahai F, Feldman J. Personal communication, 2000.
11. Dorner F. Validation of virus removal and inactivation in the course of the manufacture of sealer protein concentrate (human) vapor heated, deficient in factor VIII, using HIV-1, HAV, and model viruses. A Preclinical Study, Internal Study No PR099403, August 22, 1996.
12. Mannucci PM, Schimpf K, Abe T, Aledort LM, Anderle K, Brettler DB, Hilgartner MW, Kernoff PB, Kunschok M, McMillan CW. Low risk of viral infection after administration of vapor-heated factor VIII concentrate. *Transfusion* 32:134-138, 1992.
13. Nowotny R, Chalupka A, Nowotny C, et al. Mechanical properties of fibrinogen adhesive material. In Winter GD, Gibbons DF, Plank H Jr, eds. *Biomaterials*. New York: John Wiley & Sons, 1982.
14. Redl H, Schlag G. Properties of different tissue sealants with special emphasis on fibrinogen-based preparations. In Schlag G, Redl H, eds. *Fibrin Sealant in Operative Medicine, General Surgery, and Abdominal Surgery*, vol. 6. Berlin: Springer-Verlag, 1986.
15. Oliver DW, Hamilton SA, Figle AA, Wood SH, Lamberty BG. A prospective, randomized, double-blind trial of the use of fibrin sealant for face lifts. *Plast Reconstr Surg* 108:2101-2105, 2001.
16. Kjaergard HK, Trumball HR. Vivostat system autologous fibrin sealant: Preliminary study in elective coronary bypass grafting. *Ann Thorac Surg* 66:482-486, 1998.
17. Man D, Plosker H, Winland-Brown JE. The use of autologous platelet-rich plasma (platelet gel) and autologous platelet-poor plasma (fibrin glue) in cosmetic surgery. *Plast Reconstr Surg* 107:229-237, 2001.
18. Baker T, Gordon H. Complications of rhytidectomy. *Plast Reconstr Surg* 40:31-39, 1967.
19. Perkins SW, Williams JD, Macdonald K, Robinson EB. Prevention of seromas and hematomas after facelift surgery with the use of postoperative vacuum drains. *Arch Otolaryngol Head Neck Surg* 123:743-745, 1997.
20. Fezza JP, Cartwright M, Mack W, Flaharty P. The use of aerosolized fibrin glue in facelift surgery. *Plast Reconstr Surg* 110:658-664, 2002.